

Bone regeneration by bodily tooth movement: Dental computed tomography examination of a patient

Elif Gündüz, DDS,^a Carlos Rodríguez-Torres, DDS,^b André Gahleitner, MD, DDS,^c Gerda Heissenberger, MD, DDS,^d and Hans-Peter Bantleon, MD, DDS, MS, PhD^e

Vienna, Austria

A 32-year-old man was examined with computed tomography before and after orthodontic treatment, and alveolar bone levels at the edentulous spaces were assessed. When the computed tomography scans were compared, 2.2 to 5.2 mm of additional craniocaudal alveolar bone remodeling by bodily tooth movement was found in the space-opening region. Bodily movement was achieved with single- and crossed-lever-arm mechanics. Root resorption measuring 1 to 4 mm was observed at the mandibular anterior region, where teeth were used for anchorage to upright the molars. (*Am J Orthod Dentofacial Orthop* 2004;125:100-6)

The center of resistance (CR) of a single-rooted tooth is located approximately 40% of the distance from the alveolar crest to the apex,¹ and the CR of a molar without periodontal reduction is located approximately in the furcation area.^{2,3} The exact location is influenced by root length, marginal bone level, and characteristics of the periodontal ligament. As the periodontal attachment and bone level are reduced, the CR moves apically.⁴ Because most adults have periodontal problems, they should undergo periodontal examination before and during orthodontic treatment. Mechanotherapy in adults should involve pure bodily tooth movement (translation) achieved with light forces to avoid overloading the periodontal tissues.⁵⁻⁷

To produce direct translation, a single force directed at the CR is needed. A single force at the bracket slot level produces uncontrolled tipping. To apply a force at the CR, lever arms can be used with any bracket system. A prefabricated lever arm (LPI, Unter Oberndorf, Maria Anzbach, Austria) is available that can be bonded to the lingual surfaces of the teeth.^{8,9} Orthodontists can also easily bend the lever arm from

rectangular (.017 × .025 in) stainless steel wire and insert the arm to the additional tube at the bands or brackets. Depending on the modification in length and shape of the lingual or buccal level arms, space closure and space opening with translation can be produced.

Here we report the effect of bodily tooth movement on the alveolar bone, produced by using single- and crossed-lever-arm mechanics. The examination was focused on the mandibular right side because this movement took place in the mandibular right second premolar region. The pretreatment and posttreatment comparison was made by computed tomography of the jaws (dental CT).

Conventional dental radiologic diagnostic methods are limited to identifying anatomic and pathologic structures of intraoral hard tissues but are prone to overlap artifacts. Compared with conventional dental radiographs, dental CT permits accurate identification and measurements in multiple planes.¹⁰⁻¹² X-ray exposure from CT can be reduced significantly, especially when newer equipment (low-dose technique) is used, with which exposure can be comparable to that with panoramic radiography.¹³

Dental CT is used in contemporary dentistry for diagnosis and treatment follow-up. In orthodontics, CT examinations are routinely used because of the high resolution and life-size image display. Multiplanar reconstructions with software programs are very helpful to the clinician in 2- and 3-dimensional biomechanical orthodontic treatment planning,¹⁴ especially for impacted teeth.^{15,16} In difficult cases in which anchorage must be increased by additional elements, such as palatal implants or bicortical screws, CT scanning is

^aPostgraduate student, Department of Orthodontics, Dental Clinic of the Vienna University, Vienna, Austria.

^bPostgraduate student, Radiodiagnostic Center, Dental Clinic of the Vienna University.

^cDirector, Radiodiagnostic Centers, Dental Clinic of the Vienna University.

^dPrivate practice, Vienna, Austria.

^eHead, Department of Orthodontics, Dental Clinic of the Vienna University. Reprint requests to: Dr Elif Gündüz, Vienna University, Department of Orthodontics, Waehring Strasse 25a, A-1090 Vienna, Austria; e-mail, elifgunduz@web.de.

Submitted, November 2002; revised and accepted, March 2003.

0889-5406/\$30.00

Copyright © 2004 by the American Association of Orthodontists.

doi:10.1016/j.ajodo.2003.03.007

needed to calculate the available bone level and to check the direction of insertion.^{17,18}

MATERIAL AND METHODS

After a periodontal examination and oral hygiene appointment, a lateral cephalometric film, a orthopantomogram, and extraoral and intraoral photographs of the patient were taken for routine orthodontic consultation and treatment planning. The oral surgeon requested that dental CT be performed to evaluate the available alveolar bone level for future implantation. A second CT examination was done after orthodontic treatment, before debonding.

CT scanning (Tomoscan SR-6000, Philips Medical Systems, Best, The Netherlands) was performed with the patient in a supine position on the scanner table. The patient's mouth was closed, and the head was fixed with a soft positioner to prevent movement artifacts. Scan thickness for the mandibular jaw was 1.5 mm, with a table feed of 1 mm. The exposure time was set to 2 seconds at 75 mA per scan, and the tube voltage was set to 120 kV. A total of 35 axial scans were performed, and the images were reconstructed with a high-resolution bone filter.

The axial and orthoradial reconstructions of the CT examination were transferred to a workstation (Easy Vision, Philips Medical Systems), and buccolingual and craniocaudal bone distances were measured with a dental software program (Dental software package 2.1, Philips Medical Systems). To enable feasible measurements and comparison of pretreatment and posttreatment CT examinations, the mandibular plane was taken as the reference line, and each orthoradial reconstruction was made vertical (90°) to the mandibular plane. The magnification was the same in both compared CT reconstructions, as can be checked by the ruler on the right side of each window (Fig 1).

After the treatment, a 6-mm space was opened in the mandibular right second premolar region for the future implantation. The distance from the mesial border of this space to pogonion was 29 mm in the CT reconstruction. The first measurement was taken from this point, and a new measurement was taken every 1 mm, for a total of 6 measurements in the space. The same steps were followed for the pretreatment CT reconstruction.

CASE REPORT AND TREATMENT PLANNING

At the orthodontic consultation, a 32-year-old man sought an esthetic profile change and dental implants in the edentulous spaces of both jaws. His dental and medical history showed nothing unusual. The patient had a typical concave Class III profile, and a light

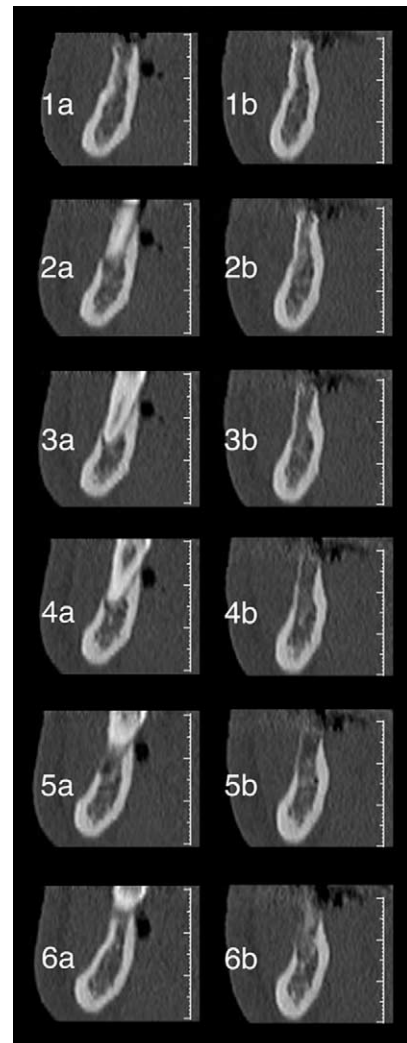


Fig 1. Orthoradial CT reconstructions of 6 measured points. **1a-6a**, Pretreatment stage; **1b-6b**, posttreatment stage.

frontal facial asymmetry to the right side. A crossbite on the right side and at the front was also observed.

The intraoral examination showed the status post-extraction of the maxillary molars and mandibular right and left first molars. The mandibular second and third molars were tipped into the extraction spaces of the first molars. The mandibular left second premolar was distally moved. In the mandibular right first molar region, clinically vertical and horizontal bone reduction was observed. A 1.5-mm gingival recession was seen at the mesial side of the mandibular right second molar, and no bleeding was observed (Fig 2). Clinically visible alveolar bone atrophy in the vertical plane was diagnosed on the orthopantomogram (Fig 3).

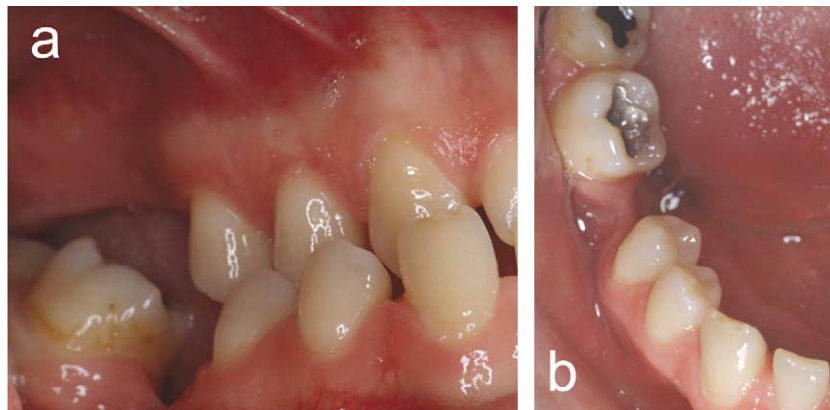


Fig 2. Intraoral photographs before treatment. **a**, Buccal view of right dental arches. Note vertical extreme bone resorption in edentulous space in mandible. **b**, Occlusal view of mandibular right dental arch. Note horizontal bone resorption in edentulous space.

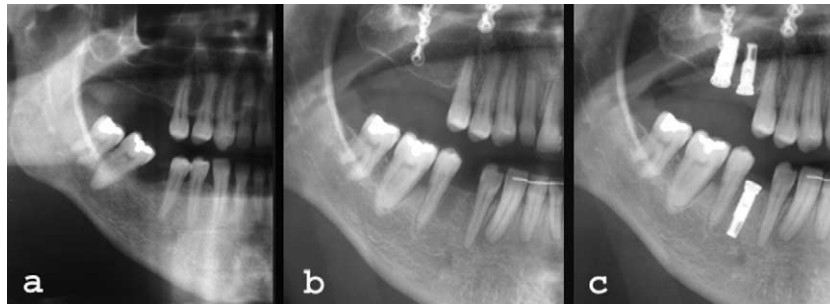


Fig 3. Orthopantomography of right side. **a**, Before treatment; **b**, after treatment; **c**, after implantation.

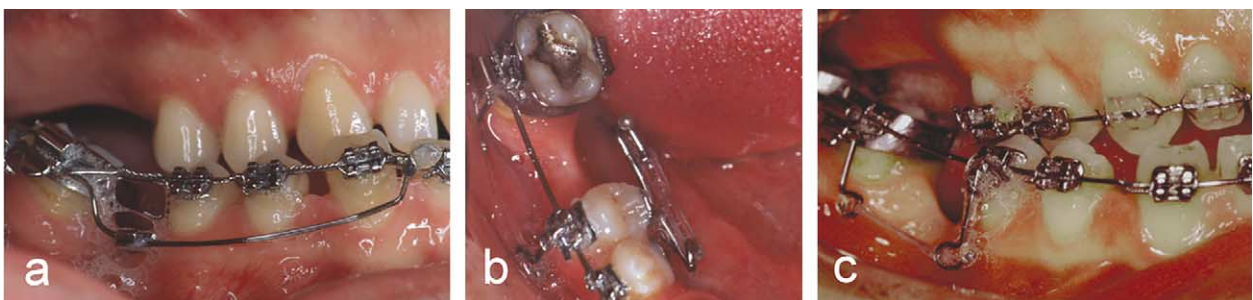

Fig 4. Intraoral photographs showing orthodontic treatment devices. **a**, Nickel-titanium stainless steel uprighting spring from lateral view; **b**, occlusal view of lingual crossed lever arms to open space between premolars; **c**, Lateral view of buccal lever arms to close space between second molar and second premolar.

Lateral cephalometric film analysis showed a skeletal Class III pattern with a retrognathic maxilla and hyperdivergent jaw relationship.

LeFort I osteotomy was recommended to correct the skeletal Class III relationship and the anterior dental

crossbite. Implants and dental esthetic correction of the maxillary front teeth by ceramic veneers were planned.

The therapy started with orthodontic treatment to prepare the maxillary and mandibular arches for maxillofacial surgery and implantation.

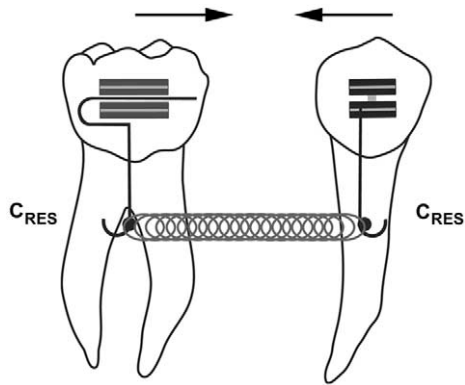


Fig 5. Free body diagram for space closure with reciprocal movement. Note lever arms and generated translatory force system at CR.

The aims of the orthodontic treatment were leveling of the maxillary and mandibular arches, expansion of the maxillary arch, uprighting of the mesially tipped mandibular molars, correcting the midline, and opening space between the mandibular premolars for the implants.

TREATMENT FOLLOW-UP AND APPLIANCE DESIGN

A straight-wire technique with a bracket slot dimension of .018 in (pretorqued brackets, Roth prescription) was used during the orthodontic treatment. After leveling the maxillary and mandibular arches, the mesially tipped mandibular molars were uprighted with the Titanol (nickel-titanium) stainless steel uprighting spring (Forestadent, Pforzheim, Germany)^{19,20} (Fig 4, *a*). A .016 × .022-in stainless steel wire was used as a guiding archwire during the entire treatment until the maxillofacial surgery.

To perform bodily movement, the space between the mandibular right premolars was opened with crossed lever arms on the lingual surface (Fig 4, *b*), and, at the same time, the space between the mandibular right second molar and right second premolar was closed by buccal lever-arm mechanics (Fig 4, *c*).^{8,9} The buccal lever arms were bent from .017 × .025-in stainless steel wire. Hooks were bent at the CR, which was measured with CT reconstructions. With a 90° bend, the lever arm was easily inserted into the second buccal tube at the molar band. The second lever arm was inserted into the vertically welded rectangle tube of the second premolar bracket. To avoid the loss of lever arms, after insertion into the tubes, the excess wires were bent with pliers, and the lever arms were ligated to the tubes. Elastic chains (Sentalloy Blue, GAC Inter-

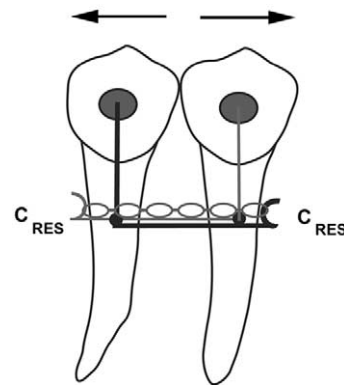


Fig 6. Free body diagram for space opening with reciprocal movement. Note crossed lever arms and generated translatory force system at CR. With pull of elastic chains, hooks will be closer, and teeth will move apart.

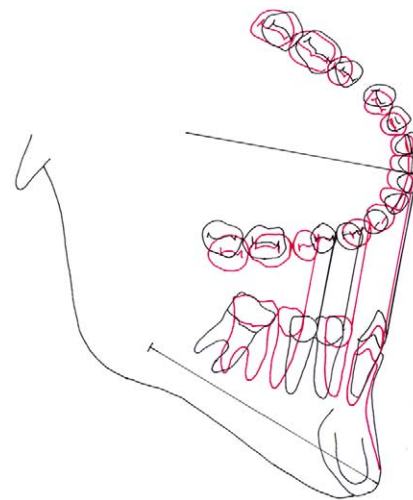


Fig 7. Superimposition of pretreatment (*black*) and posttreatment (*red*) cephalometric tracings for mandible according to Björk and occlusogram of dental arches.

national, Bohemia, NY) were used as a power source between the hooks. Space closure was produced with the reciprocal pull of the teeth at the CR via elastic chains between the hooks (Figs 4, *c*, and 5).

Modified prefabricated lever arms (.032-in stainless steel) were used on the lingual surfaces of both premolars. The lever arms were marked at the CR, and each was bent 90°, facing each other. The arms were left until they crossed each other and ended at a distance equal to or greater than the desired space between teeth. Elastic chains (Sentalloy Blue) were used as a power source between the hooks, but the use of closed coil springs is also possible. With the pull of the elastic

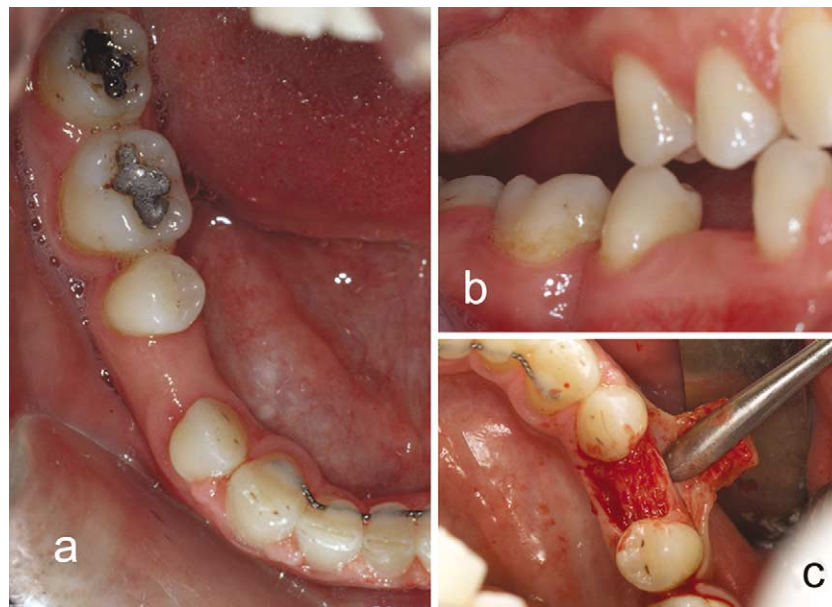


Fig 8. Intraoral photographs after treatment. **a**, Occlusal view of mandibular right dental arch. **b**, Buccal view of mandibular right dental arch. Note fold of soft tissue between mandibular right second premolar and second molar. **c**, View of regenerated bone before implantation.

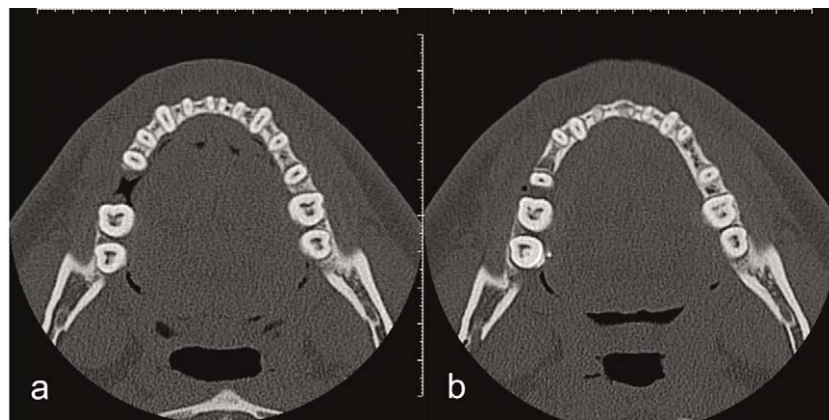


Fig 9. Axial CT slides of mandible at same level. **a**, Before orthodontic treatment; **b**, after orthodontic treatment. Note root resorption at apices of front teeth.

chains, the hooks will be closer and the teeth will move apart in different directions; thus the space will be opened (Figs 4, *b*, and 6).

RESULTS

The mandibular right first molar was uprighted and moved 2 mm mesially, as seen in the occlusogram (Fig 7). The measured bone level mesial to the mandibular right first molar showed only 0.6 mm of caudocranial new appositional bone. In the posttreatment photographs, an apparently gingival fold between the second

premolar and the first molar was seen over the newly formed crestal bone (Fig 8). In the CT examination of the same point, the shape of the bone does not show an acute angle but, rather, a round, buccal concavity.

The alveolar bone remodeling between the premolars was the intended result of space opening by bodily tooth movement, and it eliminated the need for bone grafting. The clinical observation during surgery (Fig 8) and the CT examinations showed that the regenerated new bone was appropriate in all dimensions for placement of implants.

Table. Comparison with dental CT orthoradial reconstructions of alveolar bone height at space-opening region before and after orthodontic treatment

Craniocaudal bone level	Distance to pogonion					
	29 mm	30 mm	31 mm	32 mm	33 mm	34 mm
Pretreatment	(1a) 26.9	(2a) 25.7	(3a) 23.6	(4a) 23.1	(5a) 23.9	(6a) 24.4
Posttreatment	(1b) 29.1	(2b) 29.1	(3b) 28.4	(4b) 28.3	(5b) 27.1	(6b) 26.6
Difference	+2.2	+3.4	+4.8	+5.2	+3.2	+2.2

Pogonion was used as reference point to superimpose CT reconstructions. Numbers in parentheses refer to corresponding panels in Figure 1.

Figure 1 shows the orthoradial reconstructions of the mandibular alveolar bone level of the mandibular right second premolar region, comparing pretreatment with posttreatment positions. The Table shows the measured level from the highest point of the alveolar crest to the mandibular caudal border. Maximum additional bone regeneration was 5.2 mm, and minimum was 2.2 mm.

Root resorption was observed at the root apex of all mandibular teeth. The resorption rates were measured with CT reconstructions. The lowest resorption rate was 1 mm, which was seen at the right second premolar and the molars' apices. The highest resorption rate was 4 mm at the right canine and right lateral incisor, which were the anchor teeth during molar uprighting (Figs 3 and 9). Figure 9, *a*, shows the axial slice of the mandible before orthodontic treatment, and Figure 9, *b*, shows the same axial slice after orthodontic treatment, with severe root resorption of the mandibular incisors.

DISCUSSION

Bone is a dynamic tissue that constantly undergoes remodeling. It is thought that the major reason for remodeling is to enable the bones to respond and adapt to the mechanical stresses that occur as a result of mechanical loading during orthodontic tooth movement.²¹

Application of a continuous force on the crown of the tooth leads to tooth movement in the alveolus by narrowing the periodontal ligament. Resorption occurs because of osteoclastic activity. At the tension side, new bone formation occurs because of osteoblastic activity. For rapid tooth movement and less-painful treatment for the patient, light forces are desired during orthodontic treatment.²² If heavy forces are used, the duration of movement is divided into initial and secondary periods. Direct bone resorption is found notably in the second period. The first period is the formation of a 1- to 2-mm-thick sterile necrotic area, called the hyalinized zone, and the undermining resorption of this zone. The magnitude of orthodontic force determines the duration of hyalinization.

In this patient, unfortunately, the magnitude of distalizing forces was not measured, but the duration of the leveling and space-opening stages was 2 years; this shows that tooth movement was not rapid.

If the teeth were moved bodily in the alveolar process over a distance, the remodeling would take place and form healthy new bone.²³⁻²⁶ Remodeling can remove or conserve the bone but cannot add to it.²⁷ Extrusive movement ideally produces no areas of compression in the periodontal ligament. It produces only tension. Light extrusive forces (25-30 cN) move the tooth and induce formation of new bone at the tension side.^{22,28-30} As seen at the superimposition of the mandible (according to Björk's technique),^{31,32} the premolars were extruded 2 mm (Fig 4). Bodily distal movement of the second premolar opened a 6-mm space. The extrusion and bodily movement resulted in bone formation, and this newly formed bone was carried to the atrophied alveolar process at the tension side. Vertically, the alveolar bone was increased a minimum of 2.2 mm and a maximum of 5.2 mm. The alveolar bone was obviously conserved after orthodontic treatment and ready for implantation.

Compared with conventional dental radiographs, low-dose dental CT permits accurate identification and measurements in multiple planes. Root resorptions were measured at the apices of every tooth in the mandible with CT reconstructions. Except for the severe root resorption at the canines, no further resorption was seen on the orthopantomogram. The lowest resorption, of 1 mm, was at the apices of the right premolars and molars, which were moved in the alveolus. The maximum resorption, of 4 mm, was at the apex of the canine, which was the anchor tooth during molar uprighting and resisted intrusive forces of the uprighting spring. This disappointing result indicates once again that intrusion must be carefully applied, with very light forces.

Lever-arm mechanics is an easy and very effective method for achieving bodily movement. Lever arms can be used with any bracket system. Ten years of clinical experience at the University of Vienna Depart-

ment of Orthodontics shows high patient tolerance and cooperation with the lever arms.

CONCLUSIONS

We suggest that the bone regeneration method by bodily tooth movement, instead of surgical bone-grafting methods, can be used under certain conditions to create healthy new bone.

We thank Prof Dr Robert Haas for the implantation and the photographs during the operation, and Helge Schoechnner for help with the CT examinations and measurements at the workstation at the Dental Clinic of the Vienna University.

REFERENCES

- Burstone CJ, Pyrputniewicz RJ. Holographic determination of centers of rotation produced by orthodontic forces. *Am J Orthod* 1980;77:396-409.
- Burstone CJ. Modern edgewise mechanics segmented arch technique. Farmington, Conn: University of Connecticut; 1975.
- Dermaut LR, Kleutgen JPJ, De Clerk HJJ. Experimental determination of the center of resistance of the upper first molar in a macerated, dry human skull submitted to horizontal headgear traction. *Am J Orthod Dentofacial Orthop* 1986;90:29-36.
- Roberts WW III, Chacker FM, Burstone CJ. A segmental approach to mandibular molar uprighting. *Am J Orthod* 1982; 81:177-84.
- Melsen B. Stand der Erwachsenen-Kieferorthopädie—wo liegen die Grenzen? [Status of adult orthodontics—where do the limits lie?] *Inf Orthod Kieferorthop* 1986;18:149-76.
- Melsen B. Tissue reaction following application of extrusive and intrusive forces to teeth in adult monkeys. *Am J Orthod* 1986; 89:469-75.
- Burstone CJ. Interviews: Dr Birte Melsen on adult orthodontics. *J Clin Orthod* 1988;22:630-41.
- Kucher G, Weiland FJ, Bantleon HP. Modified lingual lever arm technique. *J Clin Orthod* 1993;27:18-22.
- Sachdeva RLC, Bantleon HP. Cantilever based orthodontics—biomechanical and clinical considerations. *Orthodontics for the next millennium*. Glendora, Calif: Ormco; 1997.
- Fuhrmann R. Three-dimensional interpretation of alveolar bone dehiscences. *J Orofac Orthop* 1996;57:62-74.
- Schadlbauer E, Fezoulidis J, Schuster G, Kalavitrinos M, Imhof H, Matejka M. Die Computertomographie in der Kieferorthopädischen und Zahnärztlich-chirurgischen Diagnostik [Diagnostic potential of computerized tomography in orthodontics and oral surgery]. *Z Stomatol* 1988;85:471-9.
- Hirschfelder U. Radiologische Übersichtsdarstellung des Gebisses: Dental-CT versus Orthopantomographie [Radiological survey imaging of the dentition: dental CT versus orthopantomography]. *Fortschr Kieferorthop* 1994;55:14-20.
- Homolka P, Gahleitner A, Kudler H, Nowotny R. A simple method for estimating effective dose in dental CT. Conversion factors and calculation examples for a clinical low dose protocol. *Rofo Fortschr Geb Rontgenstr Neuen Bildgeb Verfahr* 2001;173: 558-62.
- Rothman SLG. Dental application of computed tomography: surgical planning for implant placement. Chicago: Quintessence; 1998. p. 8-43.
- Freisfeld M, Dahl IA, Jager A, Drescher D, Schuller H. X-ray diagnosis of impacted upper canines in panoramic radiographs and computed tomographs. *J Orofac Orthop* 1999;60:177-84.
- Bodner L, Bar-Ziv J, Becker A. Image accuracy of plain film radiography and computed tomography in assessing morphological abnormality of impacted teeth. *Am J Orthod Dentofacial Orthop* 2001;120:623-8.
- Bernhart T, Vollgruber A, Gahleitner A, Dörtbudak O, Haas R. Alternative to the median region of the palate for placement of an orthodontic implant. *Clin Oral Impl Res* 2000;11:595-601.
- Freudenthaler JW, Haas R, Bantleon H-P. Bicortical titanium screws for critical orthodontic anchorage in the mandible: a preliminary report on clinical applications. *Clin Oral Impl Res* 2001;12:358-63.
- Wichelhaus A, Sander FG. Entwicklung und Testung einer neuen NiTi-SE-Stahl- Aufrichtefeder [The development and testing of a new NiTi-SE-steel uprighting spring]. *Fortschr Kieferorthop* 1995;56:283-95.
- Sander FG, Wichelhaus A. Klinische Anwendung der neuen NiTi-SE-Stahl-Aufrichtefeder [The clinical use of the new NiTi-SE-steel uprighting spring]. *Fortschr Kieferorthop* 1995;56:296-308.
- Hill PA, Orth M. Bone remodelling. *Br J Orthod* 1998;25:101-7.
- Graber TM, Vanarsdall RL Jr. *Orthodontics. Current principles and techniques*. 3rd ed. St. Louis: Mosby; 2000.
- Liou EJW, Huang CS. Rapid canine retraction through distraction of the periodontal ligament. *Am J Orthod Dentofacial Orthop* 1998;114:372-81.
- Engelking G, Zachrisson BU. Effects of incisor repositioning on monkey periodontium after expansion through the cortical plate. *Am J Orthod Dentofacial Orthop* 1982;82:23-32.
- McLain JB, Proffit WR, Davenport RH. Adjunctive orthodontic therapy in the treatment of juvenile periodontitis: report of a case and review of the literature. *Am J Orthod Dentofacial Orthop* 1983;83:290-8.
- Fischer JC. American Board of Orthodontics case report. *Am J Orthod Dentofacial Orthop* 1988;94:1-9.
- Frost HM. Wolff's law and bone's structural adaptations to mechanical usage: an overview for clinicians. *Angle Orthod* 1994;3:175-88.
- Van Venrooy JR, Yukna RA. Orthodontic extrusion of single-rooted teeth affected with advanced periodontal disease. *Am J Orthod Dentofacial Orthop* 1985;87:67-74.
- Laino A, Melsen B. Orthodontic treatment of a patient with multidisciplinary problems. *Am J Orthod Dentofacial Orthop* 1997;111:141-8.
- Salama H, Salama M. The role of orthodontic extrusive remodelling in the enhancement of soft and hard tissue profiles prior to implant placement: a systematic approach to the management of extraction site defects. *Int J Periodontics Restorative Dent* 1993;4:312-33.
- Björk A. Facial growth in man studied with the aid of implants. *Acta Odont Scand* 1955;13:9-34.
- Björk A, Skieller V. Normal and abnormal growth of the mandible. A synthesis of longitudinal cephalometric implant studies over a period of 25 years. *Eur J Orthod* 1983;5:1-46.